ScientificScholar®
Knowledge is power
Publisher of Scientific Journals

www.surgicalneurologyint.com

Surgical Neurology International

Editor-in-Chief: Nancy E. Epstein, MD, Clinical Professor of Neurological Surgery, School of Medicine, State U. of NY at Stony Brook.

SNI: Pain

Editor
Jeff Brown
Neurological Surgery, P.C.; Great Neck, NY, USA

SNI
Open Access

Case Report

Facial pain as an initial manifestation of intramedullary cervical spinal cord tumor: A case report and literature review

Vidzhai Dzhafarov[1], Jamil Rzaev[1,2], Galina Moysak[1,2], Eugenia Voronina[3]

[1]Department of Functional Neurosurgery, Federal Center of Neurosurgery, Nemirovich-Danchenko 132/1, [2]Department of Neuroscience, Institute of Medicine and Psychology, Novosibirsk State University, Pirogova, [3]Department of Pathology, Novosibirsk State Medical University, Krasnyy Prospekt 52, Novosibirsk, Russia.

E-mail: *Vidzhai Dzhafarov - mvijayd@hotmail.com; Jamil Rzaev - jamilrzaev@gmail.com; Galina Moysak - moysak_galina@mail.ru; Eugenia Voronina - vorev@inbox.ru



***Corresponding author:**
Vidzhai Dzhafarov,
Department of Functional Neurosurgery, Federal Center of Neurosurgery, Nemirovich-Danchenko 132/1, Novosibirsk, Russia.

mvijayd@hotmail.com

Received : 04 November 2019
Accepted : 16 June 2020
Published : 04 July 2020

DOI:
10.25259/SNI_546_2019

Quick Response Code:

ABSTRACT

Background: Facial pain resembling trigeminal neuralgia is not a common clinical feature of cervical spinal cord tumor. Depending on nature of the facial pain, differential diagnosis tends to include neurovascular conflict, multiple sclerosis, cerebellopontine angle tumors, herpes zoster, facial injuries, and other conditions involving trigeminal nerve, ganglion, and root. Here, we present a unique case of pain in trigeminal distribution due to an intramedullary tumor in the upper cervical spinal cord.

Case Description: A 27-year-old male was admitted with complaints of intense facial pain on the right side lasting for several years. MRI revealed an intramedullary lesion at the C1 level and no signs of a neurovascular conflict or a demyelination. This lesion was removed microsurgically, with the subtotal resection immediately abolishing the pain and causing no additional neurological deficit. Histological analysis revealed ganglioglioma, Grade 1. After 5-day hospital stay, the patient was discharged home; 2-year follow-up showed no tumor recurrence on MRI and persistent relief of facial pain.

Conclusion: Secondary trigeminal neuralgia may be explained by a pathological process in vicinity of the spinal trigeminal nuclei. Removing the tumor may be expected to provide complete and lasting pain relief.

Keywords: Facial pain, Ganglioglioma, Intramedullary tumor, Secondary trigeminal neuralgia, Spinal cord tumor, Trigeminal neuralgia

INTRODUCTION

Surgical treatment of facial pain includes many kinds of procedures such as microvascular decompression (MVD), radiofrequency rhizotomy, percutaneous balloon compression, glycerol gangliolysis, stereotactic radiosurgery, trigeminal nucleotomy, motor cortex stimulation (MCS), and mass lesion resection.[4] The choice of procedure depends on clinical features and MRI findings as well as on etiology, previous surgery, a patient's desires, and fitness. Investigation of the entire trigeminal system and pathways may be useful for the detection of pain generator and choice of appropriate procedure. In this light, we describe an unusual case of facial pain due to intramedullary upper cervical spinal cord tumor.

CASE DESCRIPTION

In 2017, a 27-year-old male patient presented to us with complaints of severe paroxysmal and continuous right-sided facial pain. He described his pain as a constant severe burning sensation with intermittent intensive lancinating (sharp) pain in the distribution of all three branches of the trigeminal nerve. This paroxysmal pain could be provoked by a light touch of the skin surface, chewing, and toothbrushing. This burning facial pain with short lasting episode of eyelid ptosis on the right side started in 2014 and later he also started experiencing severe paroxysmal pain that did not respond to oral carbamazepine but improved with pregabalin (75 mg). Over the years, the pain worsened and the medication dose had to be increased. In 2016, a Gamma Knife radiosurgery (90 Gy) was performed in another institution, targeting the right trigeminal nerve root, but no pain improvement was observed during subsequent 15 months. By that time, the patient was taking pregabalin (600 mg) with partial control of the pain. He suffered minor side effects but other anticonvulsants failed to produce any significant pain reduction. His had no history of any head or neck injuries, sinus or dental surgery, cancer, or any facial pain in his family. Neurological examination was normal except for allodynia, dysesthesia, and hyperpathia in the area of pain combined with symmetric slight increase in deep tendon reflexes. There were many paroxysmal pain trigger zones on the skin of the right side of the face. Pain intensity according to the numeric rating scale was 9 (other scalings were: BPI – 103, BNIPS – 5, and DN4 – 6). MRI examination detected an intramedullary lesion located at the upper cervical (C0-C1) level on the right side; there was no evidence of any neurovascular conflict or other relevant findings [Figures 1-3].

After ruling out other possible reasons for trigeminal pain, a decision was made to resect the lesion. In the operating room, C1 posterior arch resection in prone position under general anesthesia with neurophysiologic monitoring was performed by the senior author (JR). Intraoperatively, the tumor was tan in color without clear borders of separation it from the normal tissue [Figure 4]. The resection was determined as subtotal [Figure 5]. Monitoring initially showed decrease of the somatosensory evoked potentials with complete recovery at the time of dural closure. The pain, dysesthesia, and hyperpathia completely resolved immediately after the surgery. There was only transient mild hypoesthesia on the side of pain as well as in distribution of C1-C2 dermatomes, soreness under the right eye. Immunohistochemical study of the surgical specimen defined the tumor as ganglioglioma, Grade I [Figure 6]. Antibodies to GFAP, S100, CD34, NeuN, and chromogranin were seen in the ganglion cells, CD68 was seen on the glial macrophages. IDH1 (R132H) stain was negative and Ki-67 index is 2–3%. The patient was discharged home in a satisfactory condition 5 days later. Twenty-four-month follow-up showed no evidence of tumor persistence or recurrence on MRI [Figure 7] and the facial pain did not return. Informed consent was obtained from the patient.

DISCUSSION

In this paper, we describe an unusual manifestation of a spinal cord tumor. In our patient, the facial pain was the only clinical sign of the ganglioglioma located in the uppermost segment of the spinal cord presenting as combination of paroxysmal flash-like and burning constant pain in the entire distribution of the trigeminal nerve. In patients with trigeminal neuralgia and coexisting neurological signs or history of neurological deficit, the entire trigeminal pathway can be considered for proper detection of a pain generator. Searching for lesion along the entire trigeminal pathway enabled us to detect a possible pain generator and select a proper treatment.[1,4] Although the exact pain mechanism is unclear, the association between tumor and facial pain is rather convincing due to close proximity of the tumor

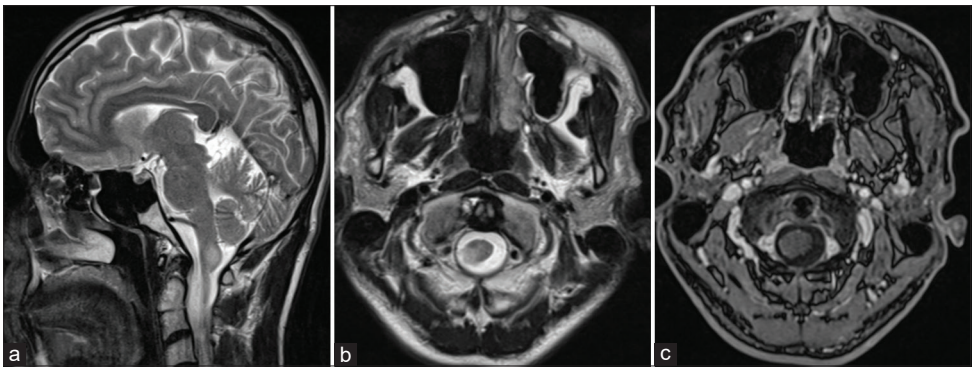

Figure 1: Preoperative MRI. (a) T2-weighted image, sagittal plane. Tumor of 14 × 10 × 6 mm in size in the caudal dorsal medulla and upper cervical cord (hypertensive signal). (b) T2-weighted image, axial plane. The tumor on the right side of the medulla has similar characteristics. (c) Contrast enhancement axial T1. No contrast enhancement in this lesion.

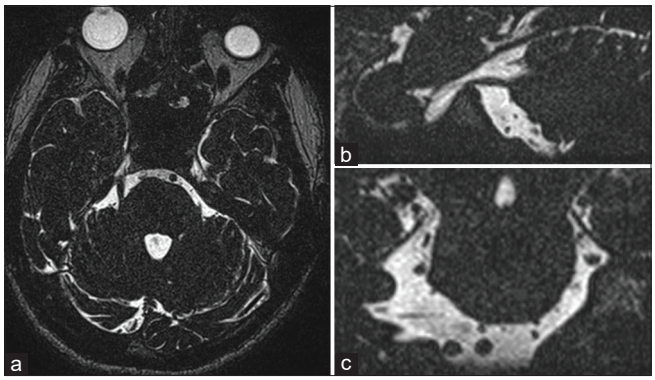

Figure 2: Preoperative MRI at the level of the cisternal part of the trigeminal nerves in CISS sequence. (a) Axial plane. (b) Sagittal plane. (c) Coronal plane. MRI demonstrates no signs of vascular conflict.

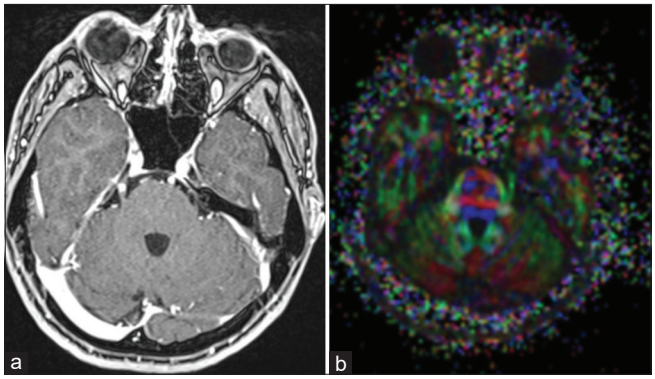

Figure 3: Preoperative MRI at the level of the cisternal part of the trigeminal nerves. (a) T1 with contrast enhancement, axial plane. The focus of homogeneous enhancement is in the cisternal part of the root that related to the stereotaxic surgery procedure that affected that area. (b) DTI sequence. Anisotropy fraction is 463 at the TREZ level.

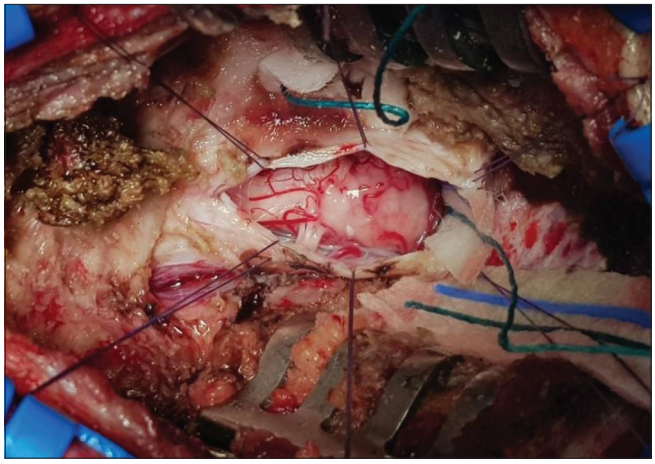

Figure 4: Intraoperative image. The tumor has glial signs, soft density, and no clear borders from normal tissue.

and the trigeminal spinal nucleus. Possible explanations may include irritation, neovascularization, edema, and compression of the trigeminal system, with the central component of pain (burning feeling) due to direct involvement of the trigeminal spinal nucleus by the tumor, and the peripheral component (the pain paroxysms) due to effects on the descending trigeminal tract [Figure 8].

There have been several similar cases described in the literature [Table 1]. Saito *et al*. presented a case of trigeminal neuralgia with additional neurological symptoms in a 45-year-old woman with intramedullary cavernous malformation.[2] Before admission, the patient experienced both motor and sensory disturbances in the extremities. MRI revealed a cavernoma at the C1 level that explained the pain and the other neurological symptoms, which were due to bleeding of the cavernoma localized closely to the pathway of the trigeminal nerve, the pyramidal and spinothalamic tracts. Stellmann *et al*. described a patient with a small intramedullary cavernoma in the brainstem that manifested with facial pain, hypoesthesia, and ptosis.[5] The pain resolved spontaneously and surgery was not performed. Another case of trigeminal neuralgia caused by an intramedullary lesion was described by Shuhui *et al*.[3] A 61-year-old woman presented with a long history of low intensity facial pain and a sudden severe neuropathic cervical itch accompanied by intense facial pain. Preoperative MRI detected a neurovascular conflict (the trigeminal nerve was compressed by the cerebellar artery) and a cavernous malformation located at C2. According to the authors, it was important to decide on the first stage of the surgery and select between MVD and intramedullary lesion resection. A careful review of the patient's history and the realization that the onset of new symptoms correlated with the bleeding had helped to opt for the resection that resulted in a good postoperative outcome. Tanei *et al*. published a case of multiple sclerosis related to the facial pain that was successfully treated with MCS.[6] The central etiology of pain became the reason to perform MCS that reduced the pain intensity by 60% during a 6-month follow-up.

Based on our experience, the management of the secondary trigeminal neuralgia associated with (or caused by) an upper cervical cord tumor should include resection of the tumor if possible. As an alternative treatment, one may consider stereotactic radiosurgery, but focusing radiation on trigeminal nerve root is unlikely to produce symptomatic improvement. Our patient underwent Gamma Knife radiosurgery of the trigeminal nerve root without any benefit, and the patient in another case[2] who underwent glycerol rhizolysis without any pain relief; both cases show ineffectiveness of destructive peripheral interventions when the source of pain is central. We postulate that in such cases, surgical intervention should target the trigeminal nuclei and tracts along with the rest of the central trigeminal pathway.

Table 1: Facial pain due to a trigeminal nuclei lesion: case review.

Author	Patient, age	MRI features	Clinical examination	Previous surgical treatment	Current treatment	Follow-up
Saito *et al.*[3]	Female, 45 y	Intramedullary hemorrhaged cavernoma at C1 level	Left facial pain in all the divisions of the trigeminal nerve, left hemiparesis, and right-sided numbness of the body. Hyperpathy in trigeminal and C2 dermatome. Deep tendon reflexes were slightly exaggerated on the left side, hypesthesia, hypalgesia in the C2-C7 dermatome	Glycerol rhizolysis without effect	Resection of cavernoma with pain relief	10 months without pain recurrence
Stellmann *et al.*[4]	Female, 55 y	Subacute hemorrhaged cavernoma in the left medulla oblongata	Left-sided facial pain with hypoesthesia and ptosis	None	Conservative, observation	n/a. Pain disappeared 3 weeks before admission
Shuhui *et al.*[5]	Female, 61 y	Right trigeminal nerve compressed by right PCA and intramedullary cavernoma at C2 level	Right-sided facial and cervical pain and cervical itch	None	Cavernoma resection with pain and itch relief in 2 weeks after surgery	12 months without pain and itch recurrence
Tanei *et al.*[6]	Male, 33 y	Demyelination in the right dorsal pons and medulla oblongata	Not paroxysmal right facial pain with facial numbness in the 2nd, 3rd divisions of the trigeminal nerve, right facial palsy, gait disorder	None	MCS with 60% pain reduction	6 months. MCS effect is the same
Our case	Male, 27 y	Tumor in right C0-C1	Right-sided facial pain with permanent burning and paroxysmal component in all the divisions of the trigeminal nerve, allodynia, dysesthesia, hyperpathy in the same area	Gamma Knife surgery of right trigeminal nerve root	Resection of tumor (ganglioglioma) with pain relief	24 months without pain and tumor recurrence

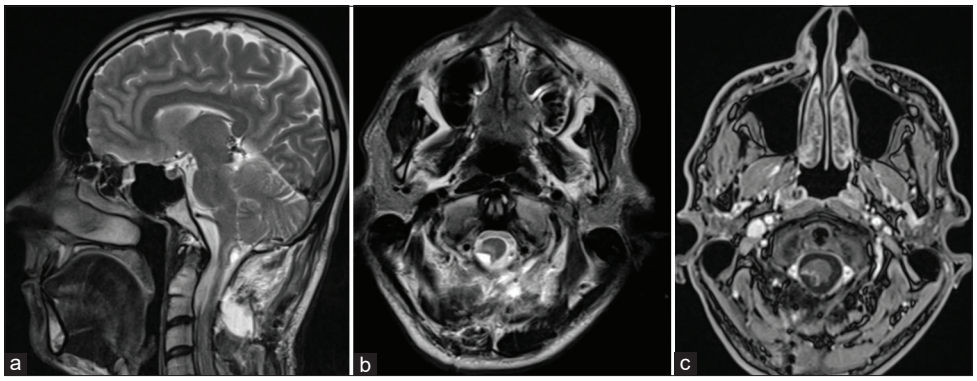

Figure 5: Postoperative MRI. (a) T2-weighted image, sagittal plane. Postoperative cavity and perifocal edema of the medulla and spinal cord. Subcutaneous postoperative edema of the soft tissues. (b) T2-weighted image, axial plane. The mass was resected, the same postsurgical changes. (c) Contrast enhancement axial T1. A small amount of contrast enhancement presents in the surgical field.

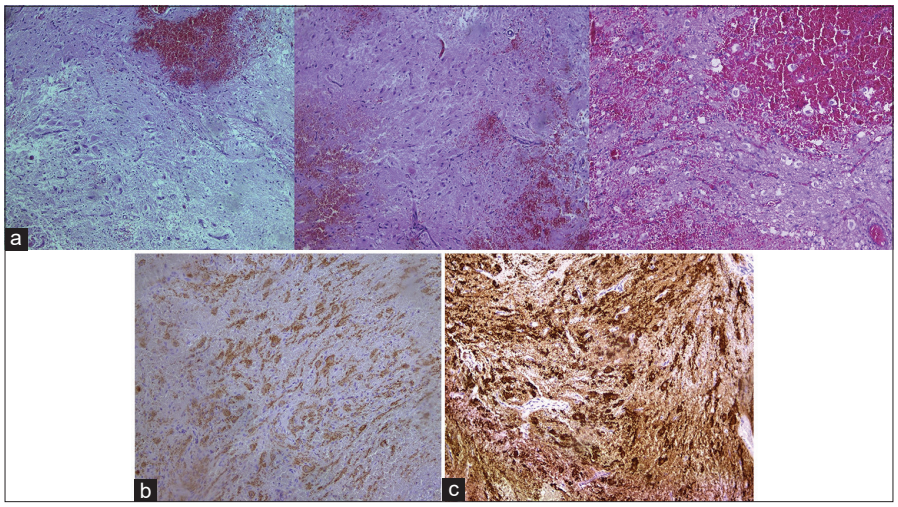

Figure 6: Histological examination. (a) H&E staining of the tumor, ×100. The sample contains rare ovoid cells with well-shaped processes as well as the sings of edema single fibers and glia cells. The neurons are often separated in a diffuse way. (b) NeuN staining, ×100. Positive staining. (c) Synaptophysin staining, ×100. Positive staining.

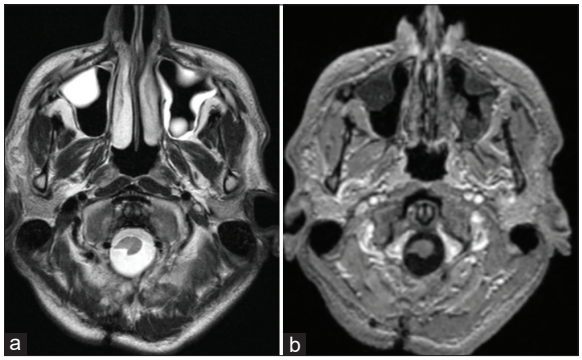

Figure 7: Postoperative MRI in 24 months. (a) T2-weighted image, axial plane. No sign of tumor. (b) Contrast enhancement axial T1. No contrast enhancement at the level of the spinal cord.

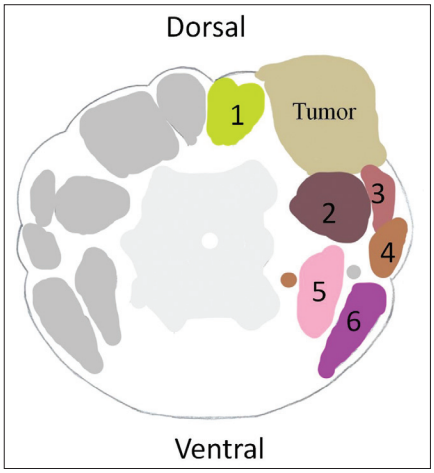

Figure 8: Anatomical relationship of the tumor and spinal trigeminal nucleus (author's scheme). (1) Fasciculi gracilis and cuneatus. (2) Spinal trigeminal nucleus. (3) Spinal trigeminal tract. (4) Posterior spinocerebellar tract. (5) Lateral corticospinal tract. (6) Lateral spinothalamic tract.

CONCLUSION

Tumors of the upper cervical cord can manifest by ipsilateral facial pain. Resection of an intramedullary lesion in the upper cervical spinal cord can result in complete and permanent relief of the facial pain.

Declaration of patient consent

The authors certify that they have obtained all appropriate patient consent.

Financial support and sponsorship

Nil.

Conflicts of interest

There are no conflicts of interest.

REFERENCES

1. Graff-Radford S, Gordon R, Ganal J, Tetradis S. Trigeminal neuralgia and facial pain imaging. Curr Pain Headache Rep 2015;19:19.
2. Saito N, Yamakawa K, Sasaki T, Saito I, Takakura K. Intramedullary cavernous angioma with trigeminal neuralgia: A case report and review of the literature. Neurosurgery 1989;25:97-101.
3. Shuhui G, Jiagang L, Siqing H, Haifeng C, Qingrong T, Bohao Z. Rare cervical intramedullary cavernous angioma with trigeminal neuralgia and cervical itch: Case report and review of the literature. Iran Red Crescent Med J 2016;18:e25151.
4. Slavin K, Nersesyan H, Colpan M, Munawar N. Current algorithm for the surgical treatment of facial pain. Head Face Med 2007;3:30.
5. Stellmann J, Kuhn M, Töpper R. Therapieresistenter gesichtsschmerz durch ein hirnstammkavernom. Aktuelle

Neurol 2007;75:552-4.
6. Tanei T, Kajita Y, Wakabayashi T. Motor cortex stimulation for intractable neuropathic facial pain related to multiple sclerosis. Neurol Med Chir (Tokyo) 2010;50:604-7.

How to cite this article: Dzhafarov V, Rzaev J, Moysak G, Voronina E. Facial pain as an initial manifestation of intramedullary cervical spinal cord tumor: A case report and literature review. Surg Neurol Int 2020;11:173.