The Contralateral Transfalcine Transprecuneus Approach to the Atrium of the Lateral Ventricle: Operative Technique and Surgical Results

Tao Xie, MD*‡
Chongjing Sun, MD*‡
Xiaobiao Zhang, MD, PhD‡¶
Wei Zhu, MD‡
Jianping Zhang, MD#
Ye Gu, MD‡
Wensheng Li, PhD§¶

‡Department of Neurosurgery, Zhongshan Hospital, Fudan University, Shanghai, China; §Digital Medical Research Center, Fudan University, Shanghai, China; ¶Shanghai Key Laboratory of Medical Image Computing and Computer Assisted Intervention, Shanghai, China; #Department of Neurosurgery, Yinzhou Hospital, Medical School of Ningbo University, ZheJiang, China

*Drs Xie and Sun contributed equally to this study.

Correspondence:
Xiaobiao Zhang, MD, PhD,
Department of Neurosurgery,
Zhongshan Hospital,
Fudan University, 180 Fenglin Road,
Shanghai, China.
E-mail: xiaobiao_zhang@163.com

Received, August 20, 2014.
Accepted, November 14, 2014.
Published Online, January 16, 2015.

BACKGROUND: Surgical approaches to the atrium of the lateral ventricle remain a challenging neurosurgical issue because of the eloquent nature of the surrounding anatomy.

OBJECTIVE: To report our operative techniques and preliminary surgical results with the contralateral transfalcine transprecuneus approach.

METHODS: A retrospective data review was performed of patients undergoing a contralateral transfalcine transprecuneus approach for the resection of lesions in the atrium of the lateral ventricle. Patients were positioned in the prone position with a 30° elevation, and a 15° rotation was used. After a contralateral parasagittal parieto-occipital craniotomy and falx incision, the corticotomy in the contralateral precuneus gyrus created a corridor to the tumor. An endoscope was used to assist with the surgery.

RESULTS: Headache was the primary preoperative symptom, which improved in all patients after surgery. After treatment, symptoms were improved in all 3 patients with hemiparesis and in 3 of 6 patients with preexisting visual deficits; symptoms were unchanged in the other 3 patients with visual deficits during the 13- to 38-month follow-up. Nine lesions were totally removed, and 1 metastatic breast cancer lesion was subtotally removed; all patients had good neurological outcomes and no operative mortality.

CONCLUSION: The contralateral transfalcine transprecuneus approach is appropriate for most lesions in the atrium of the lateral ventricle. It provides a wider surgical angle (especially for the lateral extension) and reduces the risk of disturbance of the optic radiation compared with the conventional approaches. The use of magnetic resonance venography-magnetic resonance imaging neuronavigation makes the procedure much easier and more accurate, and the neuroendoscope adds to the visualization of the microscope and can reduce surgical complications.

KEY WORDS: Atrium, Contralateral, Lateral ventricle, MRV, Neuroendoscope, Surgical approach

Operative Neurosurgery 11:110–118, 2015 DOI: 10.1227/NEU.0000000000000643

Surgical approaches to the atrium of the lateral ventricle present unique neurosurgical challenges due to the eloquent nature of the surrounding anatomy.[1] Although several approaches, including the superior parieto-occipital approach, the transtemporal approach, the lateral temporoparietal approach, the posterior transcallosal approach, and the posterior interhemispheric parieto-occipital approach, have been suggested for accessing this area, they are more or less associated with neurological deficits or a narrow working corridor (Figure 1).[1-3] We previously used the contralateral transfalcine transprecuneus approach in 2 meningiomas at the atrium of the lateral ventricle[4] and found that the approach could provide a wider surgical angle and reduce the incidence of complications compared with conventional approaches. Thus, it has become a practical surgical approach for lesions in the atrium of the

ABBREVIATIONS: MPRAGE, 3-dimensional magnetization-prepared rapid gradient-echo; **MRV,** magnetic resonance venography; **TOF,** time-of-flight

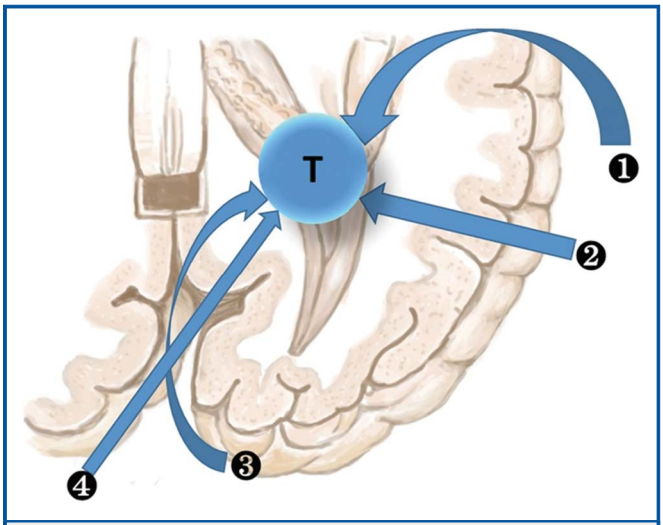

FIGURE 1. *Approaches to the atrium of the lateral ventricle. T represents the tumor within the atrium. 1, subtemporal approach; 2, transcerebral/transparietal approach; 3, posterior interhemispheric transprecuneus approach; 4, contralateral transfalcine transprecuneus approach.*

lateral ventricle. In this report, we describe the operative technique and surgical results in more detail. The operations were performed by the senior author (X.Z.).

METHODS

After approval by the Zhongshan Hospital Review Board, Shanghai, China, we retrospectively reviewed the medical files, surgical reports, and imaging studies of 10 patients with lesions in the atrium of the lateral ventricle treated with the contralateral transfalcine transprecuneus approach at the Zhongshan Hospital, Fudan University, from March 2011 to May 2014.

Of the 10 patients, 7 were female and 3 were male. They were 43 to 73 years of age with an average age of 52 years. In all of the patients, headache was their dominant clinical symptom. In addition, 3 patients had hemiparesis, and 6 patients had hypopsia and hemianopsia.

Three-dimensional magnetization-prepared rapid gradient-echo magnetic resonance imaging (3-D MPRAGE MRI) and time-of-flight (TOF) magnetic resonance venography (MRV) MRI were performed preoperatively. These imaging data were used for registration of the neuronavigation system (Excelim-04 Image-guide System, Fudan Digital Medical Company, Shanghai, China).

Surgical Procedure

After induction of general endotracheal tube anesthesia, patients were placed in the prone position. Their body and head were elevated 30°, and their head was placed in 3-pin fixation and turned approximately 15° to the side contralateral to the lesion to allow gravity to retract the contralateral parieto-occipital lobe (Figure 2). Registration of the image-guided system was performed. An 8-cm straight-line skin incision was made inferior to the lambda and perpendicular to the sagittal sutures. A contralateral parasagittal parieto-occipital craniotomy extending across the sagittal sinus was performed. The dura mater was opened in a semicircular fashion with the base reflected toward the superior sagittal sinus. The medicisterna was opened to release the cerebrospinal fluid (CSF). The splenium of the corpus callosum was identified. Once this area was reached, the falx was cut parallel to the line that was 1 cm inferior to the superior sagittal sinus, and the dura was opened in an arc fashion extending from the superior sagittal sinus toward the straight sinus posteroinferiorly and the inferior sagittal sinus anteroinferiorly (Figure 3).

Three-dimensional MRV neuronavigation and mini-Doppler imaging were used to ascertain these sinuses. The precuneus gyrus on the target side was then identified with neuronavigation using the parieto-occipital sulcus as a landmark. A longitudinal corticotomy was made in the precuneus gyrus to expose the medial side of the tumor. After debulking of the tumor, the blood supply was eliminated. Finally, the capsule was dissected, and the tumor was completely removed. The neuroendoscope provided a wider viewing angle for revealing the inferior sagittal sinus and straight sinus, removing the intraventricular clot, as well as inspecting for residual tumor and bleeding. The flap of the falx was closed with continuous sutures, and then the dura mater, bone flap, galea, and skin were closed layer by layer.

RESULTS

Of the 10 patients, 5 had fibroblastic meningioma, 2 had anaplastic meningioma, 1 had cavernous hemangioma, 1 had metastatic breast cancer, and 1 had choroid papillary carcinoma. These tumors were located on the left side in 5 patients and on the right side in the other 5 patients; they were 2.8 to 6 cm in diameter with an average diameter of 4.3 cm.

Total resection was achieved in 9 patients, and subtotal resection was achieved in 1 patient. There was no surgical mortality. In addition, 1 patient was treated with a total endoscopic contralateral transfalcine transprecuneus approach. In this case, the microscope was not used. Microscopic instruments, including the Cavitron Ultrasonic Surgical Aspirator and bipolar TAKE-APART forceps (Karl Storz GmbH & Co, Tuttlingen, Germany), were directed to the surgical area outside the endoscope to remove the tumor. In the process of tumor removal, the endoscope was fixed to a pneumatic holding arm (Karl Storz GmbH & Co) so that the tumor could be removed with both hands, and the endoscope could be adjusted as was needed.

Headache was the primary preoperative symptom, and all patients showed improvement after surgery. Hemiparesis, which was exhibited by 3 patients, also improved after treatment. Preexisting visual deficits were improved in 3 of 6 patients and did not worsen or further develop in the other 3 patients after surgery.

The mean operative time for all patients was 3 hours and 35 minutes. The estimated blood loss was less than 200 mL; none of these patients required intra- or postoperative blood transfusion.

Neurological outcomes as scored by the modified Rankin Scale were recorded during the 13 to 39 months of follow-up. Good outcomes (modified Rankin Scale scores of 0-1) were observed in 90% of patients (Table).

DISCUSSION

Managing lesions located in the atrium of the lateral ventricle is challenging because they are located deeply and surrounded by

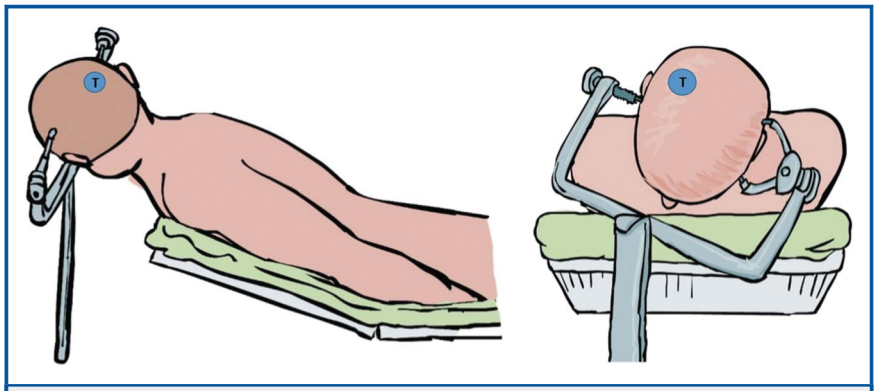

FIGURE 2. *The patient position in the contralateral transfalcine transprecuneus approach. The prone position with a 30° elevation of the body and the head with 15° rotation can optimize the advantages of this approach. T, tumor.*

eloquent structures and white matter tracts.[1] The selection of the best operative approach to this site is still controversial.[5]

In general, the ideal approach should provide the shortest working distance and largest working angle to the center of the lesion without jeopardizing the functional cortex or white matter tracts.[6] The superior parietal occipital approach, the transtemporal approach, or the lateral temporal parietal approach opens a direct route to the atrium; however, these approaches may cause visual field deficits, dyslexia, agraphia, or apraxia or increase the chance of seizures. The posterior approaches (including the posterior transcallosal and the interhemispheric parieto-occipital approach) may avoid the optic radiation surrounding the roof and the lateral wall of the atrium, but have a narrow working corridor.[1]

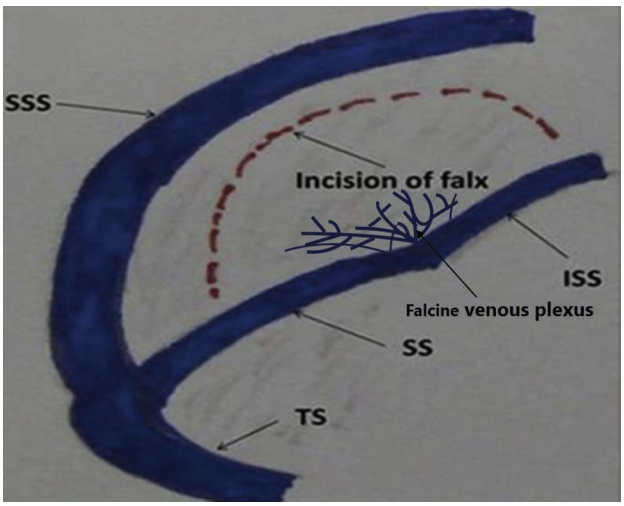

FIGURE 3. *Diagram depicting the view of the contralateral transfalcine transprecuneus approach. The planned incision of the falx (dotted line) is shown. ISS, inferior sagittal sinus; SS, straight sinus; SSS, superior sagittal sinus; TS, transverse sinus.*

In 1995, Goel[7] described the transfalcine approach to contralateral hemispheric tumors and found that it could provide a wide exposure without the need for traversing or retracting vital cerebral cortex. Wang et al[8] conducted a cadaveric study on the contralateral transfalcine transprecuneus approach, in which the working angle was 44.5° on average (range, 33°-58°), which was much greater than the 25.8° (range, 11°-38°) in the classic posterior interhemispheric transprecuneus approach. Their results indicated that the contralateral transfalcine transprecuneus approach could provide a wider surgical angle and reduce the incidence of complications compared with the conventional approaches.

We acknowledge the excellent work in cadaveric studies and describe several examples of success from our own clinical experience.

Preoperative Evaluation

The visual examinations reflect the potential relationships between the tumor and the optic radiations (Figure 4).[9] The detailed preoperative imaging studies should include multiple-sequence MRI. The position, shape, and growth path of the tumor and whether there is ventricular obstruction or periventricular edema may affect the selection of the surgical approach.[1] In our case series, patients 4 and 7 had recurrent meningiomas and had undergone the lateral transcortical approach. Their preoperative MRI showed that the normal anatomy of the ipsilateral brain was disturbed, and the ipsilateral surrounding brain was severely adhesive and edematous (Figure 5). However, in this situation, the contralateral transfalcine transprecuneus approach can be a better choice.

Operative Preparation

In the past decade, neuronavigation systems have become a fundamental tool for neurosurgeons. Three-dimensional

TABLE. Summary of the Contralateral Transfalcine Transprecuneus Approach[a]

Patient	Sex	Age, y	Presentation	Location	Size, Diameter, cm	Pathology	Visual Field		Outcome (mRS Score)	
							Preop	Postop	Preop	Postop
1	F	52	Headache, dizziness	Left trigone	4.6	Meningioma (WHO I)	No deficit	No deficit	1	0
2	M	73	Headache, walking instability	Right trigone	2.8	Meningioma (WHO I)	No deficit	No deficit	2	2
3	F	59	Headache, hemianopsia	Left trigone	3.2	Cavernous hemangioma	Right homonymous hemianopsia	Maintained	1	0
4	F	38	Headache, hypopsia	Right trigone	4.5	Meningioma (WHO III)	Left: left hemianopsia; right: left superior quadrantanopia	Maintained	1	1
5	F	39	Headache, dizziness, amaurosis	Left trigone	3.8	Meningioma (WHO I)	No deficit	NO deficit	1	0
6	M	53	Hemiparesis, hypopsia	Right trigone	5.5	Meningioma (WHO I)	Left: left hemianopsia; right: left superior quadrantanopia	Improved	2	1
7	F	51	Headache, dizziness, hemianopia	Left trigone	3.9	Meningioma (WHO I)	Homonymous hemianopsia	Improved	1	0
8	M	43	Unconsciousness, hypopsia	Right trigone	6	Meningioma (WHO III)	Left: left hemianopsia; Right: left inferior quadrantanopia	Maintained	4	1
9	F	51	Headache, hemiparesis	Right trigone	5.5	Metastatic mucinous adenocarcinoma	No deficit	No deficit	3	0
10	F	64	Headache, hemiparesis, hypopsia	Left trigone	3.5	Choroid papillary carcinoma	Right homonymous hemianopsia	Improved	2	1

[a]mRS, modified Rankin Scale; Preop, preoperatively; Postop, postoperatively; WHO, World Health Organization.

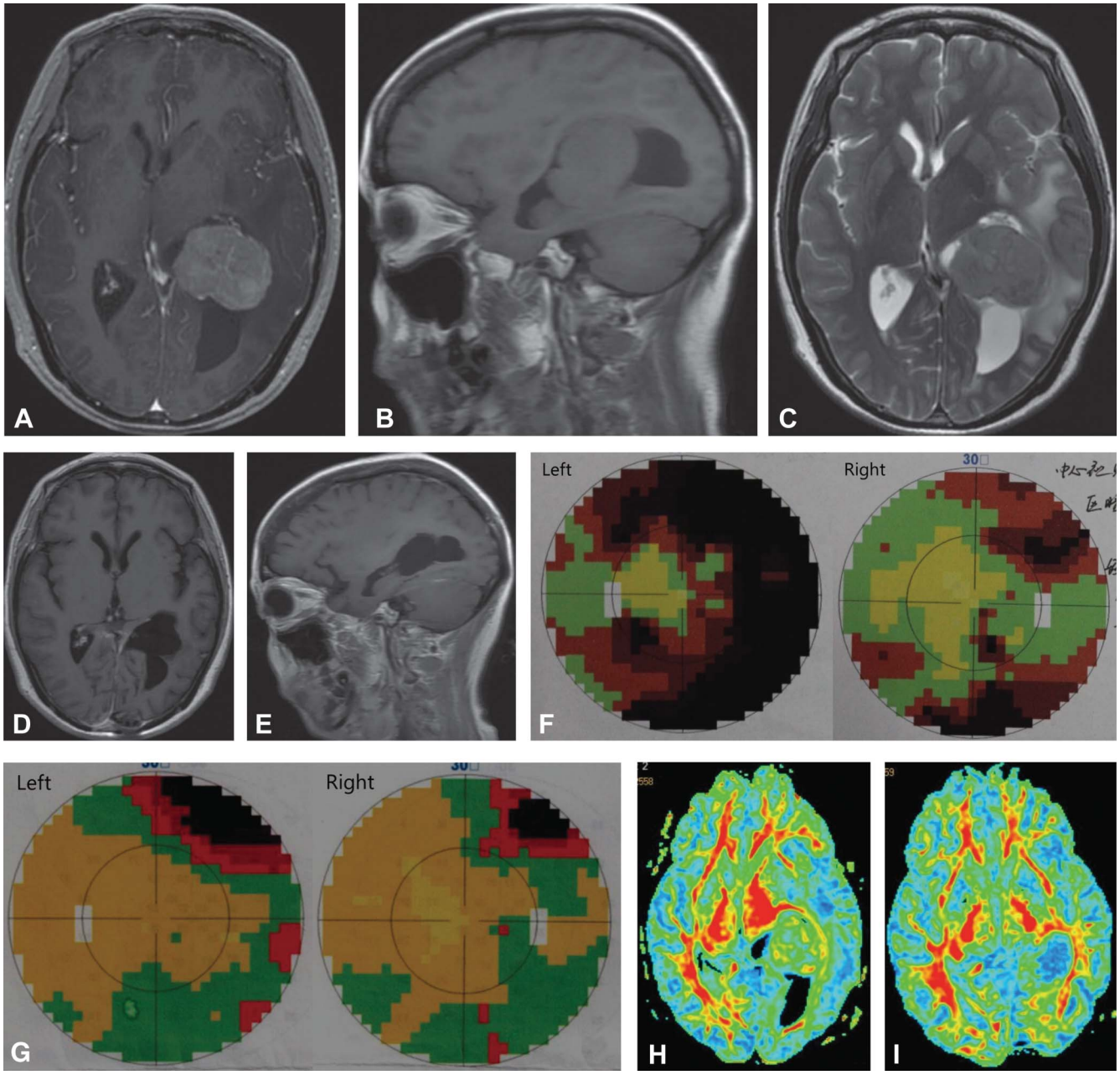

FIGURE 4. *Patient 7. Preoperative magnetic resonance images demonstrate a meningioma in the left trigone of the lateral ventricle on axial T1-weighted with contrast (**A**) and sagittal T1-weighted (**B**) images. **C**, the obvious peritumoral edema is shown on axial T2-weighted images. Postoperative magnetic resonance images demonstrated the complete resection of the meningioma on axial T1-weighted (**D**) and sagittal T1-weighted (**E**) images. **F**, visual field defects were observed on the preoperative cyclogram. **H**, the optic radiations (diffusion tensor imaging-fraction anisotropy) were pressed by the tumor. **G**, **I**, after 1 year of follow-up, the visual fields and optic radiations (diffusion tensor imaging-fraction anisotropy) were apparently improved after the operation.*

MPRAGE MRI provides better delineation of brain structures.[10] TOF-MRV sequencing has been widely accepted for the imaging of the intracranial venous system.[11] The raw DICOM data from 3-D MPRAGE and TOF-MRV sequence were input into the neuronavigation system. The 3-D reconstruction neuronavigation images can locate the inferior sagittal sinus, straight sinus, and the contralateral precuneus gyrus. The position of the patients is especially important when applying this contralateral

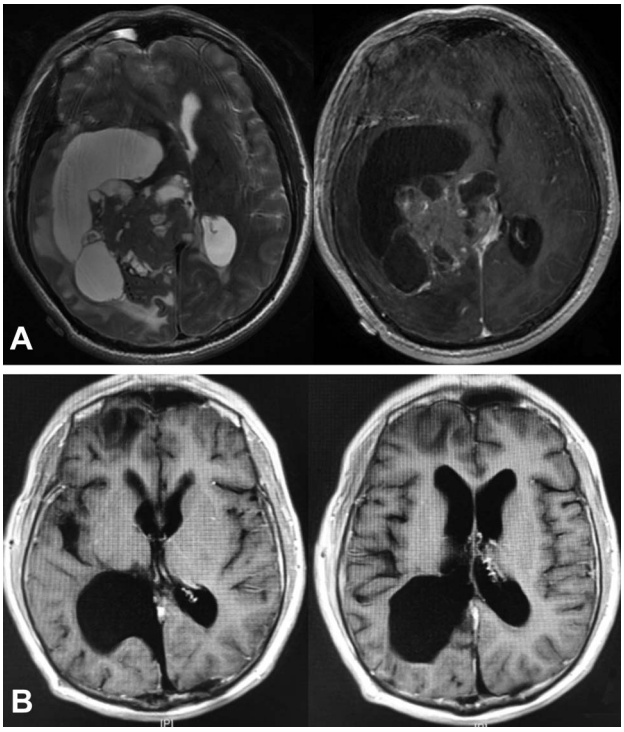

FIGURE 5. *Patient 8. A 40-year-old man has a recurrent edematous meningioma (World Health Organization III) as shown on the axial T2-weighted and T1-weighted with contrast images (**A**). **B**, postoperative axial T1-weighted with contrast images demonstrated complete resection using a contralateral approach.*

approach.[12] The prone position with a 30° elevation of the body offers optimal venous drainage and reduces intracranial pressure. Gravity can be used as a natural retractor and the 15° rotation allows gravity to act as an effective natural retractor, thereby minimizing the risk of damage to the ipsilateral visual cortex.

Intraoperative Nuances

The number of veins draining into the superior sagittal sinus between the coronal suture and the lambdoid suture is considerably greater than the veins before the coronal suture or after the lambdoid suture.[13,14] The incision after the lambdoid suture can avoid the bridging veins. No bridging vein was encountered in our series. A contralateral parasagittal parieto-occipital craniotomy extending across the sagittal sinus minimizes the degree of retraction and enlarges the interhemispheric space, whereas the downward parieto-occipital lobe retracted by gravity can enlarge this angle to obtain more free space. Cutting the falx is an essential step in this approach. This arc style of incision can avoid the falcine venous plexus. The anatomic study of the falcine venous plexus by Tubbs et al[15] suggests that most falcine veins (excluding the venous sinus) in the falx cerebri were in its posterior one-third, especially in the inferior two-thirds within this posterior one-third. The MRV neuronavigator could locate these sinuses, and the endoscope could add to visualization of these sinuses with the microscope (Figures 6A and 6B). It is good practice to avoid injury to the contralateral gyrus by incising the dura mater layer by layer. In addition, during the process of tumor resection, as the medial part of the tumor is removed, its lateral part will be pulled downward by gravity and pushed toward the midline by the swollen hemisphere, which facilitates further removal. After removal of the tumor, the neuroendoscope (Karl Storz rigid endoscope, Hopkins II telescopes [18 cm, ϕ 4 mm, 0°, 30°]) can provide a supplemental view of the body of the lateral ventricle and the temporal horn to check for any residual tumor and to remove the iatrogenic clot, avoiding postoperative obstructive hydrocephalus and fever (Figures 6C-6F).[16] The endoscopic procedures were achieved using standard 2-hand microsurgical techniques with enhanced visualization provided by the endoscopic image.

Recent anatomic studies confirm that the entire lateral wall of the lateral ventricle is covered by the optic radiations, and the medial wall of the lateral ventricle in the area of the trigone is entirely free of the optic radiations.[9] The contralateral transfalcine transprecuneus approach can effectively adopt this point. Our follow-up using perimetry and diffusion tensor imaging tracking of the optic radiations for vision and visual field injury in our series showed that all patients had good vision and visual field outcomes and no new vision and visual field injury developed.

For the ipsilateral interhemispheric approach, the narrow working area and angle may be the largest problem. For some large or edematous tumors, it is very difficult to release CSF. The excessive retracting may result in a navigation shift. The contralateral approach not only provides better lateral exposure and a wider surgical angle but also uses the falx to serve as a buffer pool to decrease the brain shift.

In our case series, most of the tumors (9 patients) had clear boundaries with lateral extension and significant peritumoral edema. The approach may have some limits regarding the lesions located purely in the midline and with blurred boundaries. Subtotal resection was achieved in patient 9 only (Figure 7). During the operation, the boundary of the tumor was unclear, and the visualization of the medial side was limited. The angled endoscope could have been helpful, but, unfortunately, it was not adopted.

Because the contralateral transfalcine transprecuneus approach involves both hemispheres, it runs the risk of damaging both visual radiations. However, the upper body is elevated to facilitate venous drainage; mannitol and hyperventilation are used to reduce intracranial pressure, and the sufficient CSF release and natural gravity-retraction provide adequate operating space. Therefore, the ipsilateral hemisphere can be protected perfectly. No newly developed or worsened visual deficits were found in any patients in our study. The contralateral approach to the atrium simply supplies another new view of this area, especially for the tumors with clear boundaries, lateral extension, and serious peritumoral edema or adhesion. This approach cannot replace the classic and common approaches, which might be safer and more efficient for less experienced surgeons.

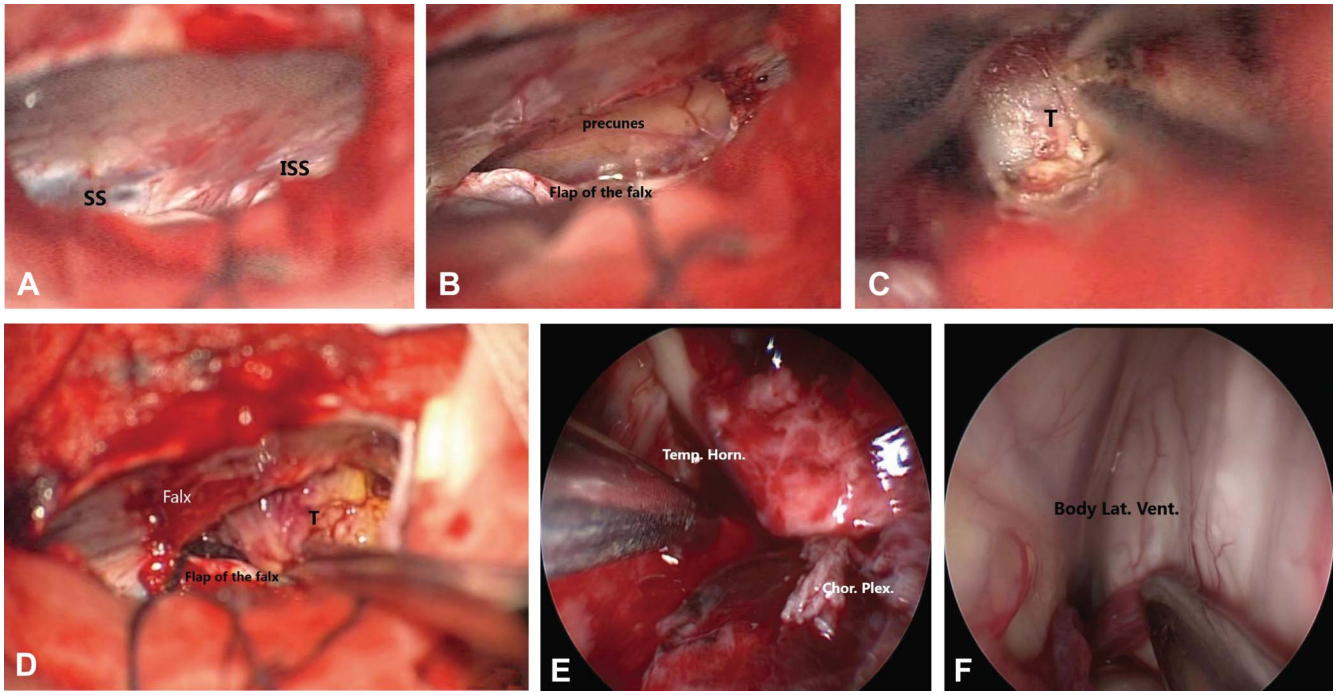

FIGURE 6. **A**, *microscopic view of the inferior sagittal sinus and straight sinus.* **B**, *after cutting the falx, the contralateral precuneus gyrus was located.* **C**, *the medial side of the tumor after the longitudinal corticotomy in the precuneus gyrus.* **D**, *after debulking the tumor, the capsule of the tumor was completely resected.* **E**, **F**, *the endoscope provided supplemental visualization of the temporal horn and the body of the lateral ventricle to check for any residual tumor and to remove the iatrogenic clot. ISS, inferior sagittal sinus; SS, straight sinus; T, tumor; Temp. Horn, temporal horn; Chor. Plex., choroid plexus; Body Lat. Vent., body of the lateral ventricle.*

CONCLUSION

The overriding concept of intraventricular surgery is not to select the shortest distance to the lesion but rather to minimize the manipulation of the neurovascular tissues, which often entails longer trajectories to achieve these specific goals.[1] Although the contralateral transfalcine transprecuneus approach has a longer trajectory, it provides a wider surgical angle (especially for the lateral extension) and reduces the risk of disturbance of optic radiation compared with other conventional approaches. The incision after the lambdoid suture can avoid the bridging veins, and extending the craniotomy across the superior sagittal sinus can enlarge the interhemispheric space. The use of MRV-MRI neuronavigation makes the procedure much easier and more

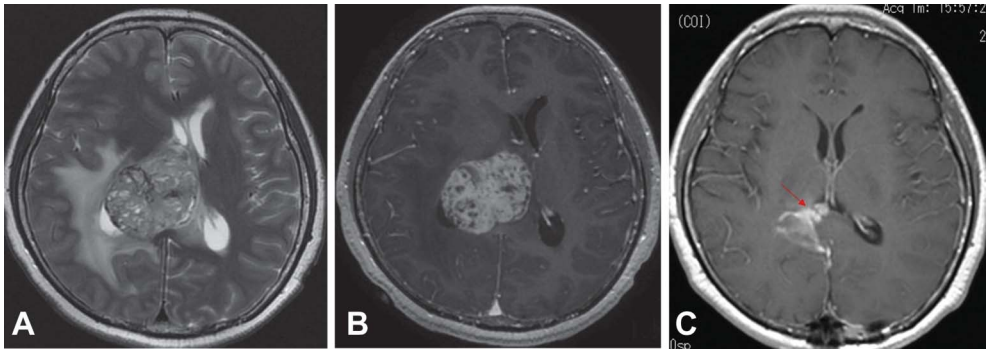

FIGURE 7. *Patient 9. A 51-year-old woman with metastatic adenocarcinoma in the atrium of the lateral ventricle.* **A**, **B**, *preoperative axial T2-weighted and T1-weighted with contrast images show that the adenocarcinoma was extended medially.* **C**, *postoperative axial T1-weighted images with contrast 2 months later demonstrated the residual tumor (red arrow).*

accurate, and the neuroendoscope provides supplemental visualization with the microscope and can reduce surgical complications.

Disclosures

This study was supported by the Shanghai Committee of Science and Technology, China (grant no. 14YF1401000). The authors have no personal, financial, or institutional interest in any of the drugs, materials, or devices described in this article.

REFERENCES

1. Yaşargil MG, Abdulrauf SI. Surgery of intraventricular tumors. *Neurosurgery*. 2008;62(6 suppl 3):1029-1040.
2. Kawashima M, Li X, Rhoton AL Jr, Ulm AJ, Oka H, Fujii K. Surgical approaches to the atrium of the lateral ventricle: microsurgical anatomy. *Surg Neurol.* 2006; 65(5):436-445.
3. Peter PS, Joseph MP. Tumors of the lateral ventricle. *Neurosurg Q.* 1997;7(4): 286-300.
4. Zhu W, Xie T, Zhang X, et al. A solution to meningiomas at the trigone of the lateral ventricle using a contralateral transfalcine approach. *World Neurosurg.* 2013; 80(1-2):167-172.
5. Izci Y, Seçkin H, Ateş O, Başkaya MK. Supracerebellar transtentorial transcollateral sulcus approach to the atrium of the lateral ventricle: microsurgical anatomy and surgical technique in cadaveric dissections. *Surg Neurol.* 2009;72(5):509-514.
6. Lucas TH II, Ellenbogen RG. Approaches to the ventricular system. *Neurosurg Q.* 2001;21:50-59.
7. Goel A. Transfalcine approach to a contralateral hemispheric tumour. *Acta Neurochir (Wien).* 1995;135(3-4):210-212.
8. Wang S, Salma A, Ammirati M. Posterior interhemispheric transfalx transprecuneus approach to the atrium of the lateral ventricle: a cadaveric study. *J Neurosurg.* 2010;113(5):949-954.
9. Mahaney KB, Abdulrauf SI. Anatomic relationship of the optic radiations to the atrium of the lateral ventricle: description of a novel entry point to the trigone. *Neurosurgery*. 2008;63(4 suppl 2):195-202.
10. Wenz F, Hess T, Knopp MV, et al. 3D-MPRAGE evaluation of lesions in the posterior cranial fossa. *Magn Reson Imaging.* 1994;12(4):553-558.
11. Lee JM, Jung S, Moon KS, et al. Preoperative evaluation of venous systems with 3-dimensional contrast-enhanced magnetic resonance venography in brain tumors: comparison with time-of-flight magnetic resonance venography and digital subtraction angiography. *Surg Neurol.* 2005;64(2):128-133.
12. Charalampaki P, Filippi R, Welschehold S, Conrad J, Perneczky A. Tumors of the lateral and third ventricle: removal under endoscope-assisted keyhole conditions. *Neurosurgery*. 2005;57(4 suppl):302-311.
13. Rhoton AL Jr. The cerebral veins. *Neurosurgery*. 2002;51(4 suppl):S159-S205.
14. Sayhan S, Guvencer M, Ozer E, Arda MN. Morphometric evaluation of parasagittal venous anatomy for intracranial approaches: a cadaveric study. *Turk Neurosurg.* 2012;22(5):540-546.
15. Tubbs RS, Loukas M, Louis RG Jr, et al. Anatomy of the falcine venous plexus. *J Neurosurg.* 2007;107(1):155-157.
16. Cappabianca P, Cinalli G, Gangemi M, et al. Application of neuroendoscopy to intraventricular lesion. *Neurosurgery*. 2008;62(suppl 2):575-597.

Acknowledgment

The authors thank Dr He Yi-Zhou for his help in drawing the illustrations for this paper.

COMMENTS

We first described the transfalcine approach to contralateral hemispheric lesions in 1995.[1-3] There have been only few subsequent articles on the subject. In their paper, the authors discussed their surgical experience with 10 cases of atrial lesions in which they have successfully adopted this approach.

The feasibility of adopting a contralateral transfalcine approach for deep-seated lesions does look attractive. I congratulate the authors for using the technique successfully in relatively formidable cases. The success achieved by them is a compliment to their microsurgical skills. The approach will necessarily involve arachnoidal dissection to minimize brain retraction, precise and wide tumor exposure, and meticulous and positive tumor dissection.

Meningiomas in the region of the atrium of the lateral ventricle can be difficult surgical issues. The depth of the lesion from the surface and the eloquence of the brain en route give plus and minus marks to all available approaches. The difficulty arises in the fact that the vascular supply from the choroidal arteries is from the depth and away from the dome of the tumor. The contralateral approach provides an avenue to the deeper part of the tumor early in the operation and the possibility of early control of vascular pedicle. In this respect, the approach appears rational. The ease of retraction of the normal over the edematous tumor−affected cortex is another positive issue in the approach. The advances in the deployment of the technique include the use of neuronavigation that can guide the surgeon toward the tumor and minimize the falcine incision. I am not convinced that an endoscope will be able to provide additional sting to the approach.

Despite some obvious advantages, there are negative issues that have kept us from using the approach on a regular basis. We recently published our experience with 50 cases of intraventricular meningiomas.[4] After our experience with the contralateral transfalcine approach for more than 20 years and with intraventricular meningiomas, we would advise against using this approach for lesions such as large atrial meningiomas. Atrial meningiomas can be quite significantly vascular lesions. Their large size and hypervascularity necessitate wide and strategic exposure. The need for retraction of the contralateral hemisphere to obtain exposure of the tumor and the potential damage to normal and frequently the only preserved visual pathway can be prohibitive. Contralateral interhemispheric exposure compared with the ipsilateral interhemispheric approach increases the distance of the tumor from the surface by few critical millimeters. The angle of the approach can be a little too acute for prolonged manipulation and dissection. The "dance" of the surgeon along with the microscope to view the circumference of the lesion may result in a bad fall. The need to expand the exposure in cases with bleeding from the tumor or to expose the breadth of the tumor may need retraction of the normal brain little more than safe limits. Damage to normal visual pathways will certainly be a distinct possibility in such a situation. The contralateral transfalcine approach can be kept in the armamentarium of a neurosurgeon. However, selection of the approach for a correct indication may be critical for safe outcome.

Atul Goel
Mumbai, India

1. Goel A. Transfalcine approach to a contralateral hemispheric tumor. *Acta Neurochir (Wien).* 1995;135(3-4):210-212.
2. Goel A. Transfalcine approach. *J Neurosurg.* 2010;113(5):1126.
3. Goel A, Nitta J, Kobayashi S. Tumor-obstructive hydrocephalus: a natural defense mechanism. In: Kobayashi S, Goel A, Hongo K, eds. *Neurosurgery of Complex Tumors and Vascular Lesions*. Philadelphia: Churchill Livingstone; 1997:373-391.
4. Goel A, Desai K, Bhaganagare A. Intraventricular meningiomas. In: Pamir N, Black P, Fahlbusch R, eds. *Meningiomas: A Comprehensive Text*. Philadelphia: Saunders Elsevier; 2010.

This paper is a retrospective review of a case series in which tumors of the atrium were approached and resected via a contralateral

transfalcine transprecuneus approach. The surgical approach was well described, with good illustrations and images, and the overall the series demonstrated excellent results, with gross total resection and minimal morbidity achieved in most cases. The authors should be commended for these results in a complex series of cases.

The rationale used for this approach was the lack of visual fibers on the medial surface of the ventricle, the relatively short distance to the tumor in some cases, and the wide working angle. Drawbacks such as the potentially longer reach and the possible injury to both occipital lobes were discussed. Although this approach was successfully used in this series, less experienced surgeons and some experienced surgeons may experience problems with this approach related to contralateral midline venous drainage, aberrant deep drainage in the posterior flax, retraction injury to the deep venous system, bilateral visual deficits, and contralateral deep ventricular bleeding without proximal control. Suggestions were made to lessen these risks.

It is important to note that the precuneus has been implicated in several brain functions and is not silent brain. Higher mental functioning, memory, and other neurocognitive functions are thought to take place in this area. The authors did not observe any cognitive side effects of the approach. This potential neurocognitive risk and the other potential risks need to be weighed against the risk of a quadrantic visual field deficit, which in many of these cases was already present and remained postoperatively despite the approach sparing these nonfunctioning tracts. It should be noted that an inferior temporal approach giving a crescentic superior quadrantic visual field deficit is usually very well tolerated by patients; does not preclude driving, reading, or working; and often is not even noticed.

Richard Byrne
Chicago, Illinois

The contralateral transfalcine transprecuneus approach to lesions in the atrium of the opposite lateral ventricle is an interesting option for some situations where the tumor extends more laterally. The approach offers a more horizontal and lateral perspective than can be achieved from an ipsilateral midline approach. However, this approach may put both hemispheres at risk with dire consequences if there are visual changes. Although gravity may do an adequate job of retracting, there can be damage to this contralateral region, whether from retraction by gravity or an actual retractor. Overall, I prefer an ipsilateral transcortical approach to the atrium even though this may not give quite as good a view of the lateral-most portion of the tumor. Use of an endoscope clearly aids in this just as it does with the proposed approach. I tend to be very protective of the opposite side so that there is no, or very minimal, chance of a bilateral injury. If a midline approach to an intraventricular lesion is chosen, this contralateral view may be better than the ipsilateral one, but only with great care.

Kalmon D. Post
New York, New York

Figure 3. Dr Michael McDermott tying a suture knot during a procedure that accomplished resection of a hyper vascular sphenoid wing meningioma.