Book Review: *Endoscopic Sinus Surgery: Anatomy, Three-Dimensional Reconstruction, and Surgical Technique, Third Edition*

By: Peter-John Wormald
Published by: Thieme Publishers, New York, NY, 2012
Hardcover: 304 pp.
Price: $179.99
ISBN: 978-1-60406-687-6

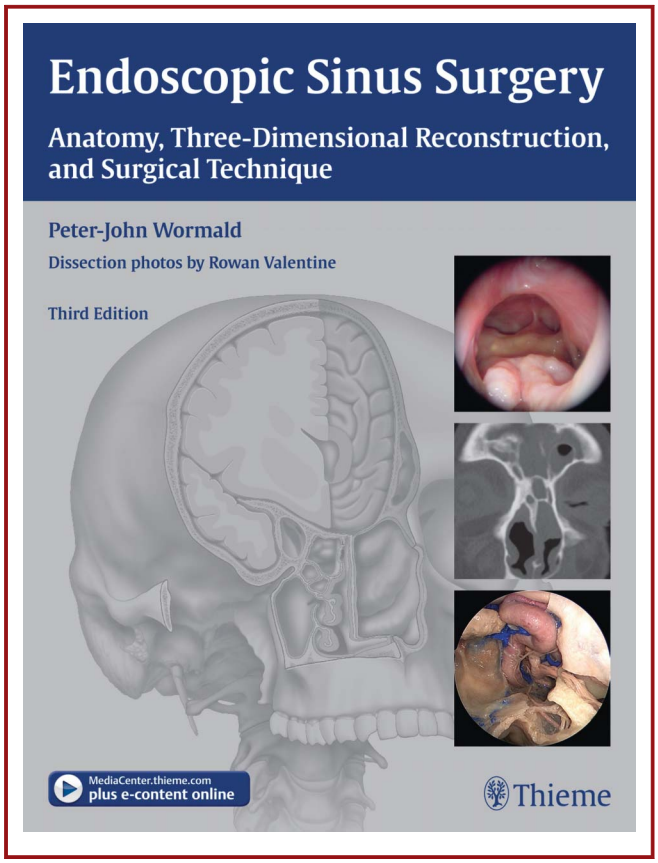

Endoscopic Sinus Surgery: Anatomy, Three-Dimensional Reconstruction, and Surgical Technique, third edition, by Peter-John Wormald, was published in October 2012. It is an updated, revised text of surgical anatomy and technique with 304 pages, 944 illustrations, and 56 accompanying online surgical videos. In comparison with the second edition of this text, 3 new chapters have been added: Anatomy of the Sphenoid and Adjacent Structures of Importance during Skull Base Surgery (Chapter 18), Endoscopic Surgery of the Craniocervical Junction (Chapter 21), and Carotid Artery and Major Vascular Injury during Endoscopic Sinus Surgery (Chapter 22). The remaining chapters have all undergone review, and some have been substantially revised. Also new to this third edition are more than 150 cadaver dissection photographs by Rowan Valentine, performed under the direction of Albert L. Rhoton Jr, in his surgical dissection laboratory at the University of Florida. The available online surgical videos are categorized into 4 sections: Basic Sinus Surgery, Advanced Sinus Surgery, Skull Base Surgery, and Transnasal Intracranial Surgery.

Peter-John Wormald is Professor and Chairman of the Department of Otolaryngology at the University of Adelaide in South Australia. With more than 200 articles referenced in PubMed and numerous research grants, Professor Wormald is an accomplished academic rhinologist. He is known worldwide among the rhinology and transnasal endoscopic surgical communities for his dedication to surgical teaching and his remarkable ability to explain even the most difficult procedures with ease. Professor Wormald is a highly sought-after speaker at rhinologic and neurosurgical dissection courses spanning various countries and continents. He has been awarded the Golden Head Mirror Award for meritorious teaching in rhinology by the American Rhinologic Society and gave the 5th Invited Kennedy Lectureship at the American Rhinologic Society meeting in 2009. Professor Wormald has also received the Australian Medical Association Significant Contribution to Medicine Award.

Professor Wormald's expertise across the depth and breadth of rhinologic, skull base, intracranial, and associated anatomy, along with his thoughtful and systematic descriptions of surgical technique, highlighted by relevant examples, make this single-author text a unique anatomic and surgical manual for the beginning or advanced rhinologic surgeon. Throughout the book, the chapter structure is visually appealing and well organized, with relatively short topic sections and subsections to orient the reader. Tables, key points, and chapter conclusions are very helpful to ensure that significant and essential issues are conveyed.

Overall, the standout features of this book are the anatomic and surgical descriptions with accompanying cadaveric dissection photos and diagrams. The text explanation of anatomy and surgical technique is thorough, logical, and presented in a manner that is easy to follow, irrespective of the level of difficulty of the anatomy or procedure being described. Moreover, nearly every point in the text is illustrated with an example in diagram, radiologic, live or cadaver endoscopic photographs, or video format, and often a combination of these modalities is used to reinforce the message. This is notably advantageous for learners of all types.

The cadaver dissection photographs contributed by Rowan Valentine are remarkable highlights of this text. Whether depicting anatomy or procedural steps, the attention to detail is superb.

Anatomic structures are clearly visualized, labeling is complete, and figure legends are appropriately detailed without being too lengthy. These outstanding photographs will be studied thoroughly by first-time readers of this text, and further reviewed and referenced well into the future.

Certain chapters and features in Professor Wormald's third edition book deserve specific mention as noteworthy strengths of this text. Chapter 6 (Anatomy of the Frontal Recess and Frontal Sinus with Three-Dimensional Reconstruction), Chapter 7 (Surgical Approach to the Frontal Sinus and Frontal Recess), and Chapter 8 (Three-Dimensional Reconstruction and Surgery of the Bulla Ethmoidalis, Middle Turbinate, Posterior Ethmoids, and Sphenoid) are exceptional in their anatomic descriptions, use of building block models for 3-dimensional construction of paranasal sinus anatomy, and use of triplanar radiologic imaging to illustrate relevant anatomic concepts. This teaching method has garnered Professor Wormald much praise in the rhinologic community. Videos 10 to 21 are pertinent for both anatomy descriptions in Chapter 6 and for surgical techniques in Chapter 7, providing the reader an opportunity to view the videos twice for reinforcement of different concepts. An important graduated approach to frontal recess and frontal sinus management is highlighted in Chapter 7, and excellent descriptions for identification of key imaging landmarks (superior meatus, posterior choanae, anterior to posterior ethmoid transition, and posterior ethmoid to sphenoid transition) are provided in Chapter 8.

Chapter 16 (Endoscopic Resection of Tumors Involving the Maxillary Sinus, Pterygopalatine Fossa, and Infratemporal Fossa), Chapter 19 (Endoscopic Resection of Clival and Posterior Cranial Fossa Tumors), and Chapter 20 (Endoscopic Resection of Anterior Cranial Fossa Tumors) must also be noted as highlights of this text. Each of these chapters addresses particularly difficult anatomy and/or demanding and potentially perilous surgical procedures. In these 3 chapters, the anatomic narrative, diagrams, and photos are extraordinary, the surgical steps are well described, and the examples are appropriately illustrative of the teaching points to be conveyed. Finally, of the newly added chapters with this third edition, Chapter 21 (Endoscopic Surgery of the Craniocervical Junction) is especially notable for its excellent cadaver dissection photographs of the anatomy of this region.

Despite its numerous strengths, *Endoscopic Sinus Surgery: Anatomy, Three-Dimensional Reconstruction, and Surgical Technique*, third edition, has some concomitant weaknesses. First, there are some technical issues with some of the videos and figures that accompany the text. While inclusion of 56 instructional videos is indeed beneficial for a book of this length, certain aspects of the videos could be improved. Many of the videos appear to be truncated at the end before apparent completion of the surgical description, some of the video narration does not coincide with the view presented on the screen, and the technical quality of some videos is not ideal. Because the videos are presented on a centralized media Web site by the publisher, rather than with a CD that accompanies the book, it is difficult to determine if these technical issues are a result of the videos themselves or their presentation online. There are also a number of videos that present very similar techniques, at times making viewing repetitive. This occurs most notably in the frontal recess surgical technique videos, especially with dissection of the agger nasi and T1 frontal recess cells, as well as with the posterior ethmoid and sphenoid sinus surgical dissection videos. In addition, a number of the live endoscopic photographs, especially in the first few chapters of the book, have poor color quality or are oversaturated, making the images more difficult to fully discern.

Second, although it is acknowledged that this text is a single-author text, throughout the book there is little discussion of alternative surgical approaches other than the techniques that Professor Wormald uses. Additional literature reference to alternate surgical methods, their potential benefits and downfalls, and their reported outcomes may provide the reader further opportunity to compare various techniques and determine what may suit his or her patient the best.

With regard to weaknesses in specific chapters and topics, the overall coverage of cerebrospinal fluid (CSF) leak diagnosis and repair throughout the text could be enriched. Chapter 3 (Imaging in Endoscopic Sinus Surgery) lacks any substantial discussion of imaging and radiologic diagnostic modalities for CSF leaks, skull base defects, and meningoencephaloceles. Chapter 12 (Cerebrospinal Fluid Leak Closure) presents numerous computed tomographic scan images and a single magnetic resonance image in the discussion of CSF leak etiology and preoperative assessment. There is little discussion and no examples of computed tomographic or magnetic resonance cisternograms, their sensitivity, specificity, or potential uses in special cases, such as patients with multiple bony skull base defects and slow or intermittent leakage of CSF. The techniques for CSF leak closure in Chapter 12 are also somewhat limited to the bathplug technique and underlay/overlay fascia lata grafting. Although these are very nice techniques that have worked well for Professor Wormald and many other surgeons, little consideration is given to other CSF leak closure techniques, additional autologous and nonautologous grafting materials, alternate free and pedicled tissue transfer, tissue glues, and absorbable vs nonabsorbable packing and support materials.

Finally, the addition of the rather short Chapter 18 (Anatomy of the Sphenoid and Adjacent Structures of Importance during Skull Base Surgery) in this third edition text adds a relatively small amount of additional information beyond what is already presented in other chapters on pituitary, vidian nerve, and clival surgery. The updated information in Chapter 18 could be divided among these other chapters in further support of the information already contained there.

Endoscopic Sinus Surgery: Anatomy, Three-Dimensional Reconstruction, and Surgical Technique, third edition, by Professor Peter-John Wormald is a delightful, well thought out, and logical anatomic and surgical text. The book has numerous strengths and a handful of weaknesses, which have been noted here. Highlighted by thorough and thoughtful anatomic descriptions,

superb cadaveric dissection photographs, and excellent description of surgical techniques, this book will remain a learning and reference tool for many rhinologists and endoscopic skull base surgeons.

Disclosure

The author has no personal, financial, or institutional interest in any of the drugs, materials, or devices described in this article.

Sarah K. Wise, MD, MSCR
Department of Otolaryngology-Head and Neck Surgery
Emory University
Atlanta, Georgia

10.1227/NEU.0000000000000281

Book Review: *SMART Approach to Spine Clinical Research*

By: Michael J. Lee, Daniel C. Norvell, Joseph R. Dettori, Andrea C. Skelly, Jens R. Chapman
Published by: Thieme Publishers, New York, NY, 2013
Hardcover: 208 pp.
Price: $99.99
ISBN: 978-3131750617

The stated purpose of this book is "to assist you in planning a quality scientific study, regardless of research experience." The editors emphasize that the planning of a study is perhaps one of the most important aspects of producing quality clinical research. To appropriately plan a worthwhile investigation, the SMART-B approach is advocated. SMART-B is an acronym for study question, searching the literature, study design, measurements, analysis, resources, timing, and bias reduction. The first 8 chapters of the text are used to detail the SMART-B approach. The ninth and final chapter does not directly discuss items related to study planning but rather consists of topics that may be of interest to a clinical investigator such as guidance on manuscript preparation and how to interpret meta-analyses. In addition to an outline, each chapter begins with a few pertinent remarks such as "A goal without a plan is just a wish." There are relevant figures, and important concepts or examples are summarized in single highlighted sentences throughout each chapter. This format is effective in maintaining the reader's attention and conveying the important details of what could be considered fairly dry material. A concise summary is also present at the end of each chapter.

The first chapter is a brief overview of the SMART-B approach, emphasizing the importance of the components and how they contribute to developing a sound clinical study. Chapters 2 through 8 provide a more comprehensive explanation of each aspect of the SMART-B algorithm. As an example, Chapter 2 recommends using the patients, intervention, comparison, and outcomes method to develop the most appropriate study question for evaluating a potential surgical treatment. The importance of a literature search and the method to construct an appropriate search of existing databases such as PubMed is the basis of Chapter 3. Chapter 4 discusses the 2 basic types of study designs, descriptive and analytic. Factors influencing selection of the best study design are discussed. The 4 categories of measurements are discussed in Chapter 5, with particular emphasis on patient-reported outcomes. Power analysis and sample size planning, as well as descriptive and analytical statistics, are the main concepts presented in Chapter 6. Chapter 7 details the need for appropriate collaborators, funding, and timing of a study. Chapter 8 discusses the various forms of bias (ie, performance bias) that can occur and suggests means to minimize each bias. Chapter 9, "Special Topics," is the longest chapter, covering somewhat disparate but interesting topics, including manuscript preparation, heterogeneity of treatment effects, systematic reviews, meta-analyses, and healthcare policy, among others.

Overall, this text accomplishes its main goal of guiding the spine care professional in designing a high-level clinical study. The SMART-B approach seems to be a straightforward algorithm that encompasses all the key aspects to be considered in planning a focused and achievable investigation. Information gleaned from this book will also improve the reader's ability to critically evaluate the literature. The text is easily readable because the concepts are presented in concise sections with appropriate case examples. The downside of these brief, readable sections, however, is the lack of detail given for certain concepts. As an example, in Chapter 5,